

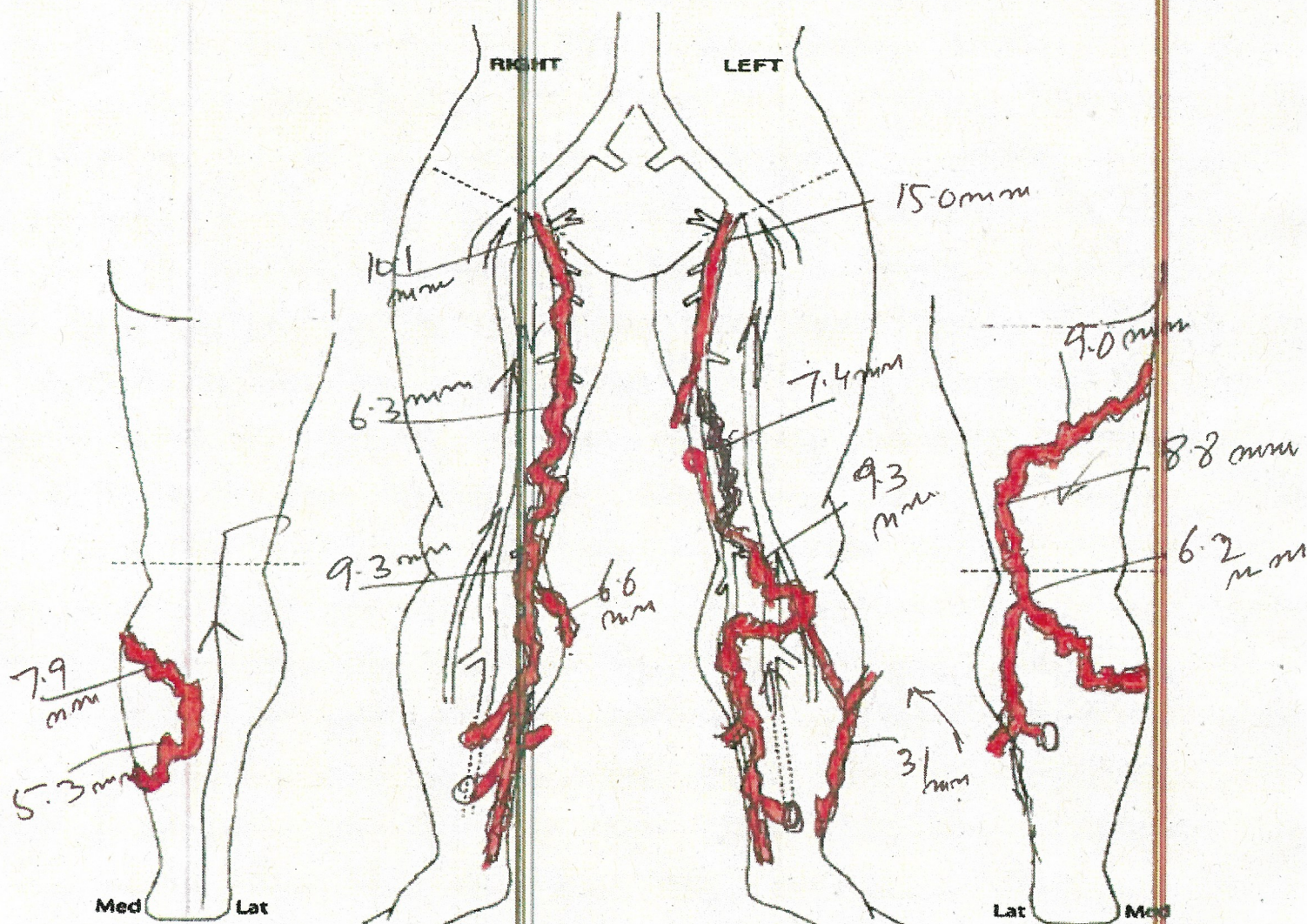
**Broomfield
VascLab**

Hosp Number

Consultant YOW

Date exam 15-05-2019

LOWER LIMB COLOUR DUPLEX VENOUS ASSESSMENT



Right;

Incompetent and tortuous LSV from SFJ in its entirety, drains in to perforators at mid calf and another 15cm above ankle (diameter 6.3mm to 10.1mm). It also gives posterior branch below knee (diameter 6.6mm), which goes posteriorly and again swings medially to join LSV above ankle.

SSV and deep veins are patent and competent.

Left;

LSV incompetent from SFJ to mid thigh (diameter 7.5mm to 15.0), from mid thigh to knee it is tortuous and thrombosed. Below knee it is incompetent and tortuous. At mid thigh LSV gives posterior tortuous vein, goes laterally and then downward to back of lateral knee (diameter 6.2mm to 9.0mm). Below back knee divides in to medial and lateral branches. Medial branch goes down ward and medially to join LSV at mid calf. Lateral branch goes anteriorly in front of calf to reach at ankle. SSV and deep veins are patent and competent.

Scan performed and reported by: Ikhlaz rana